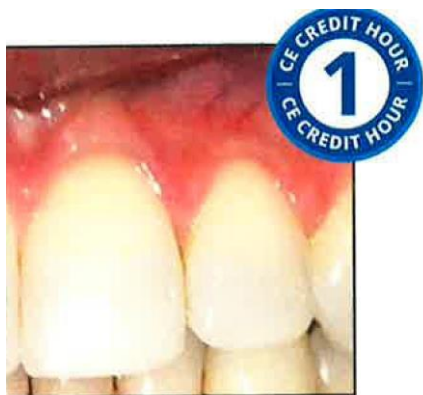

**dentalcare.com**

Continuing Education

## Anatomy & Histology of the Gingival Unit and Basic Oral Hygiene



**Course Author(s):** Courtney Ison, RDH, MS

**CE Credits:** 1 hour

**Intended Audience:** Dental Hygienists, Dental Students,  
Dental Hygiene Students

**Date Course Online:** 08/01/2019

**Last Revision Date:** N/A

**Course Expiration Date:** 07/31/2022

**Cost:** Free

**Method:** Self-instructional

**AGO Subject Code(s):** 10

**Online Course:** [www.dentalcare.com/en-us/pcQfessfono l-edu cation/ce-courses /ces92](http://www.dentalcare.com/en-us/pcQfessfono l-edu cation/ce-courses /ces92)

**Disclaimer:** Participants must always be aware of the hazards of using limited knowledge in integrating new techniques or procedures into their practice. Only sound evidence-based dentistry should be used in patient therapy.

### **Conflict of Interest Disclosure Statement**

- The author reports no conflicts of interest associated with this course.

### **Introduction - Gingival Unit Anatomy**

Anatomy & Histology of the Gingival Unit and Basic Oral Hygiene continuing education course will examine the characteristics of the gingival unit and discuss basic recommendations necessary for achieving and maintaining the health of the gingiva.

## Course Contents

- Overview
- Learning Objectives
- Glossary
- The Periodontium
- Clinical Anatomy of the Healthy Gingival Unit
- Microscopic Anatomy of the Healthy Gingival Unit (Histology)
- Local Contributory Factors Influencing Gingival Health
- Basic Oral Hygiene
- Conclusion
- Course Test
- References
- About the Author

## Overview

The periodontium includes the tissues that support and surround the teeth including the free gingiva, attached gingiva, alveolar mucosa, cementum, periodontal ligament, and alveolar process. Having a basic understanding of these structures allows clinicians to provide the best possible care to their patients by allowing them to accurately assess a patient's oral health status. The free gingiva, attached gingiva, and alveolar mucosa make up the gingival unit and are the only components of the periodontium that are clinically visible.

## Learning Objectives

**Upon completion of this course, the dental professional should be able to:**

- Name and describe the components of the periodontium.
- Name and describe the components of the gingival unit.
- Describe and identify basic anatomy and histology of the gingival unit.
- Describe the characteristics of healthy gingiva.
- Understand the role of local contributory factors influencing gingival health.
- Explain the recommendations for toothbrushing and flossing.

## Glossary

Before beginning the study of the gingiva and oral hygiene procedures it is necessary to define several terms commonly used.

**apical** - Towards the root.

**cementoenamel junction (CEJ)** - Junction of cementum (root) and enamel (crown).

**coronal** - Towards the chewing surface of the tooth.

**gingival margin** - Portion of the free gingiva that is located at the CEJ.

**histology** - The study of tissues.

**interdental papilla** - Gingiva extending between two adjacent teeth.

**pellicle** - Thin film made of saliva, cells, and bacteria that starts the plaque formation process.

**periodontium** - Collective term for the structures that support the teeth.

## The Periodontium

The periodontium is comprised of the gingival unit and the attachment unit or attachment apparatus. The units are further broken down as follows:<sup>1</sup>

### Gingival Unit (Figure 1):

- Free gingiva
- Attached gingiva
- Alveolar mucosa<sup>1</sup>

### Attachment Unit (Figure 2):

- Cementum
- Alveolar Process
- Periodontal Ligament

## Clinical Anatomy of the Healthy Gingival Unit

It is important to understand normal anatomy, histology, and clinical characteristics of the gingival unit in order to accurately assess a patient's periodontal health status. Once a basic understanding has been established, the hygienist then has the tools needed to understand the pathologic changes that occur during the process of disease.

The gingival tissue in the oral cavity is the most important tissue of the oro-facial region for dental professionals to know and understand.<sup>2</sup> The gingiva forms a protective covering over

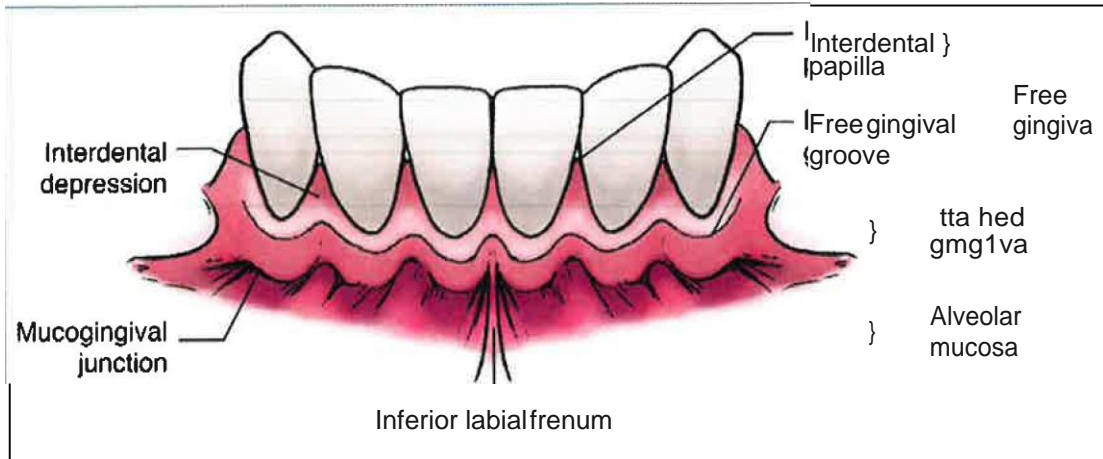


Figure 1. Gingival Unit.

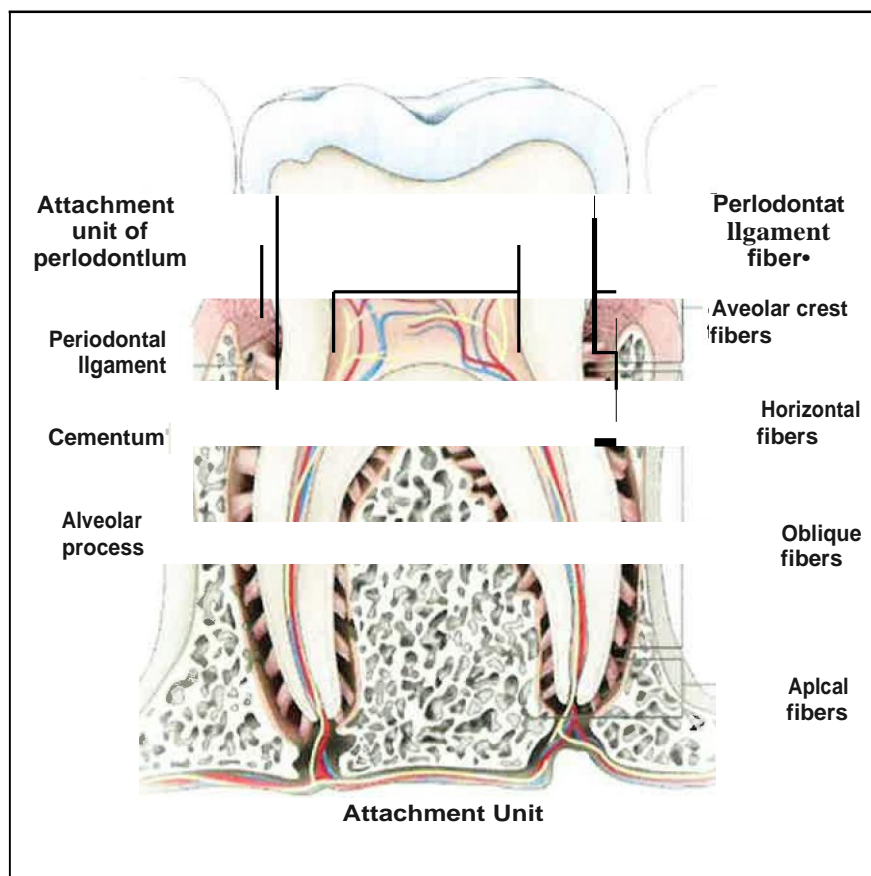


Figure 2. Attachment Unit.

the other components of the periodontium and is well adapted to protect against mechanical insults.<sup>3</sup> The color of the gingiva is normally salmon pink (except for normal pigmentation in patients with various ethnic backgrounds).<sup>3</sup> The pink color of gingiva indicates a lack of

inflammation; inflammation of the gingiva is an indicator of gingival disease. Healthy gingival epithelium is firmly attached to the underlying cementum and connective tissue covering the alveolar process.<sup>3</sup> The space between the free gingiva and the tooth is the gingival sulcus

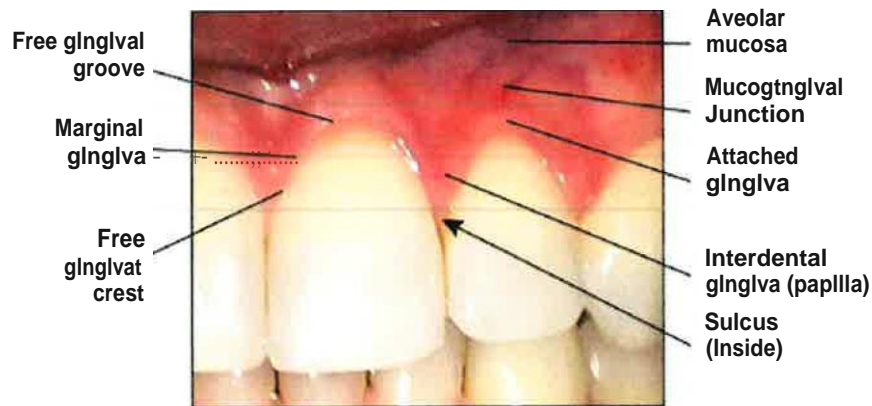


Figure 3. Gingiva.

and is measured using a periodontal probe; a healthy gingival sulcus is 3 mm or less in depth and does not bleed when probed or brushed.<sup>1</sup> Free gingiva is the portion of the gingiva that is unattached and is continuous with the attached gingiva. In health, the marginal gingiva follows the scalloped pattern established by the contour of the cemento-enamel junction (CEJ) of the teeth.<sup>2</sup> The part of the gingival tissue that fills in the triangular-shaped spaces between the teeth is the interdental papilla. Interdental papilla is shaped differently depending on the size of the tooth. Posterior teeth are wider buccolingually than anterior teeth, making the interdental papilla of an anterior tooth significantly smaller. Apical to the contact area, interdental papilla assumes a concave shape between the facial and lingual gingival surfaces, forming the gingival col.<sup>2</sup>

Attached gingiva is continuous with the free gingiva and is not movable, as it is bound to the bone and cementum by connective tissue fibers.<sup>3</sup>

The alveolar mucosa is movable and is separated from the attached gingiva by the mucogingival junction. This tissue is darker in color, thin, soft, and loosely attached to underlying bone.<sup>1</sup>

### Microscopic Anatomy of the Healthy Gingival Unit (Histology)

The attached gingiva and free gingiva share similar histology because both are considered masticatory mucosa (due to its rubbery surface texture and resiliency).<sup>2</sup> Because the

free gingiva and attached gingiva protect the underlying periodontium, the epithelium is mainly keratinized. The cells that make up the free gingiva and attached gingiva are described as keratinized stratified squamous epithelium. However, there is a small area of nonkeratinized stratified squamous epithelium in the sulcus at the col area. The alveolar mucosa is also made of nonkeratinized stratified squamous epithelium (which is the most common type of epithelium in the oral cavity).<sup>2</sup>

All forms of epithelium have an adjoining connective tissue located deep to the basement membrane; in the case of the oral mucosa, this connective tissue is considered the lamina propria.<sup>2</sup> The main fiber group of the lamina propria is collagen fibers, which provide the firm attachment of gingiva to cementum and alveolar bone. The lamina propria also contains the vascular supply for the gingiva.

### Local Contributory Factors Influencing Gingival Health

Gingivitis is the first stage in the disease process of the gingiva and is a reaction that the body has to the bacteria present in dental biofilm (plaque). Many local factors can increase plaque deposition and retention, inhibit plaque control, and contribute to the development of gingivitis and periodontitis; these factors are considered contributory because they do not by themselves initiate gingival inflammation.<sup>3</sup> Some examples of local factors include calculus, anatomic factors, iatrogenic factors (caused by materials and techniques used in dentistry),

and traumatic factors (such as food impaction or chemical injury). These local factors may contribute to the disease process of the gingiva. Proper oral hygiene can control many of these factors so that the disease process is never initiated or help reverse the process in those situations where the inflammatory process has already begun.


### Basic Oral Hygiene

Within minutes after eruption or after all surfaces have been thoroughly cleaned, pellicle begins to form and is fully formed within 30-90 minutes.<sup>4</sup> Biofilm accumulation occurs when bacteria attach to pellicle. Biofilm becomes increasingly more difficult to remove the longer it is attached to the tooth surface, and eventually hardens into a calcified dental biofilm known as calculus. A regimen that is used to control this biofilm accumulation consists of basic toothbrushing and interdental cleaning/flossing.

Toothbrushing is the mechanical removal of biofilm and debris from the tooth structure and oral structures such as the gingiva and the tongue. The process of care is a standard that dental professionals should follow in the treatment of patients and includes an implementation phase to provide patients with education and recommendations, such as choosing the best type of toothbrush, brushing method, frequency, and duration of brushing. Two toothbrushes that are given as

options for patients are manual and power toothbrushes. When choosing a manual or power toothbrush, a soft bristled toothbrush is usual for most patients due to the risk of trauma with harder bristled brushes. While there are many different brushing methods, the method commonly recommended to healthy patients is a sulcular brushing method known as the Bass method. The Bass method is widely accepted as an effective method for dental biofilm removal.<sup>4</sup> The procedure for this method includes directing toothbrush bristles apically at a 45° angle to the long axis of the tooth into the gumline, pressing lightly, and using vibratory strokes. For the occlusal surfaces of the teeth, a 90° angle is recommended. It is also standard to recommend brushing at least 2 times per day for at least 2 minutes each session.

Flossing is the standard recommendation for interproximal cleaning for many patients but is most effective when interdental papillae are present and there has not been loss of attachment with root surface exposure.<sup>4</sup> Although there are several different types of dental floss, research shows that there is no difference between waxed and unwaxed floss on the effectiveness of biofilm removal.<sup>4</sup> The method for flossing that is typically recommended is to use 18 inches of floss wrapping it around the middle fingers of both hands and using index fingers and thumbs to gently guide the floss past each contact area without causing trauma to the interdental



**Figure 4.** Use about 18 inches of floss, so you have a clean piece to use on each tooth in the cleaning process.

papilla. Once the floss has passed the contact area, the floss should be adapted to both tooth surfaces one at a time using a C-shape then sliding up and down over the tooth surface at least twice. It is recommended to floss at least once per day prior to toothbrushing.

### **Conclusion**

The process of care that a dental professional should follow includes assessment, diagnosis, planning, implementation, documentation, and

evaluation.<sup>4</sup> One role of a dental professional is to accurately assess the gingival health of a patient and implement appropriate patient care and oral hygiene recommendations. Part of this role is to accurately assess and document the gingival health of a patient through oral examination. From these assessments, the dental professional can discuss findings with patients and promote gingival health through appropriate oral hygiene recommendations.

### Course Test Preview

To receive Continuing Education credit for this course, you must complete the online test. Please go to: [www.dentalcare.com/en-us/professional-education/lce-courses/lce592/test](http://www.dentalcare.com/en-us/professional-education/lce-courses/lce592/test)

- 1. Which of the following is NOT considered part of the gingival unit?**
  - A. Free gingiva
  - B. Attached gingiva
  - C. Alveolar process
  - D. Alveolar mucosa
- 2. What part of the oral cavity forms a protective covering over the other components of the periodontium and protects against trauma?**
  - A. Dentin
  - B. Gingiva
  - C. Cementum
  - D. Periodontal Ligament
- 3. A healthy gingival sulcus has a measurement of \_\_\_ mm or less and does not bleed when probed or brushed.**
  - A. 2
  - B. 3
  - C. 4
  - D. 5
- 4. The interdental papilla become wider the more \_ \_ \_ \_ \_ the tooth.**
  - A. posterior
  - B. anterior
  - C. buccal
  - D. lingual
- 5. The tissue of the alveolar mucosa can be described as all of the following EXCEPT:**
  - A. Dark
  - B. Soft
  - C. Thick
  - D. Loosely attached
- 6. Nonkeratinized stratified squamous epithelium makes up all of the following parts of the oral cavity EXCEPT:**
  - A. Attached gingiva
  - B. Alveolar mucosa
  - C. Lining mucosa
  - D. Col area
- 7. All of the following statements are true regarding lamina propria EXCEPT:**
  - A. Made of connective tissue.
  - B. Collagen fibers are the main fiber group.
  - C. Contains the vascular supply for the gingiva.
  - D. Located superficial to the basement membrane.

8. **All of the following describe local contributory factors of gingival disease EXCEPT:**
- A. Increase plaque deposition and retention
  - B. Inhibit plaque control
  - C. Directly initiate gingival inflammation
  - D. Contribute to the development of periodontitis
9. **Which statement is false in regards to basic oral hygiene recommendations?**
- A. A soft bristled toothbrush is the best manual brush to recommend to a healthy patient.
  - B. A sulcular brushing method is the best method to recommend to a healthy patient.
  - C. The best interproximal cleaning aid to recommend to a healthy patient with no special needs is dental floss.
  - D. Waxed dental floss is the best type of floss for every person.
10. **Dental professionals have a responsibility of assessing gingival health. Which of the following steps are NOT taken after assessment has occurred?**
- A. Document findings
  - B. Discuss findings with patients
  - C. Provide patients with appropriate recommendations
  - D. Provide patients with appropriate care
  - E. All of the above steps are taken after assessment has occurred



## References

1. Brand RW, Isselhard DE. Anatomy of orofacial structures: A comprehensive approach. St. Louis, MO. Elsevier. 2019. 77-81.
2. Fehrenbach, MJ, Popowics T. Illustrated dental embryology, histology, and anatomy. St. Louis, MO. Elsevier/Saunders. 2016.14,105-111,123-124.
3. Weinberg MA, Theile CM, Froum SJ, et al. Comprehensive periodontics for the dental hygienist. Boston, MA. Pearson. 2015. 3-4,73.
4. Wilkins EM, Wyche C, Boyd L. Clinical practice of the dental hygienist. Philadelphia, PA. Lippincott Williams & Wilkins. 2017. 12-13,257,454,474.

## Additional Resources

- No Additional Resources Available.

## About the Author

### Courtney Ison, RDH, MS



#### **Clinical Instructor and Private Practice Dental Hygienist**

After completing a degree in dental hygiene, Mrs. Ison was appointed as a clinical instructor at the University of Cincinnati Blue Ash College. She then completed a Master of Science in Health Education and was appointed as Adjunct Professor for Oral Anatomy, Histology, and Embryology. Mrs. Ison is currently practicing as a Registered Dental Hygienist in a private practice setting and has continued her role as a clinical instructor at UCBA.

Email: [courtney\\_ison@hotmail.com](mailto:courtney_ison@hotmail.com)